

## **What airway device would you choose for a 4kg baby undergoing an elective MRI? ETT or LMA?**

APA Hot Topic March 2017

### **Background**

To obtain a good MRI image requires the cooperation of the patient since the environment can be noisy, claustrophobic, uncomfortable, warm and the scanning time lengthy. Many children undergo MRI scans with distraction techniques or, in neonates, following a feed. Considerable debate exists as to whether anaesthesia or sedation is best for children undergoing MRI scans (1). The question this month was “what airway device would you choose for a 4kg baby undergoing an elective MRI?” This editorial will focus on those children undergoing general anaesthesia rather than sedation for their MRI scans.

Safety is paramount in the MRI environment and specific safety issues are well described (2). With regards to airway and ventilation, patients are often positioned at a significant distance from the anaesthetist, using long ventilator tubing, often in a different room. It may be difficult to visualise the airway once the scan is underway. If reintubation is required, the patient must be removed from the scan room, or MRI compatible equipment used.

Perhaps the traditional view is that small infants are best managed by intubation and ventilation, whilst older patients may breathe spontaneously on an LMA (3). This generalisation may have shifted somewhat with the advent of new LMA designs and with increasing familiarity in using LMA in younger patients. However, there is not a large body of evidence to inform us as to whether ETT or LMA is safer in children undergoing MRI scans.

A French survey of the anaesthetic practice of 28 university hospitals for paediatric patients undergoing MRIs found that tracheal intubation was mandatory for 36% of hospitals. However 80%, routinely used either tracheal intubation or LMA (4).

A study of children undergoing anaesthesia or sedation for MRI/CT, noted one incidence of laryngospasm of 140 children undergoing general anaesthesia (0.7%) (5). This occurred en route to the post-anaesthesia care unit, was managed with suxamethonium and bag and mask ventilation and they recovered uneventfully. It is not recorded in the study whether the patient had an LMA or ETT for their general anaesthetic.

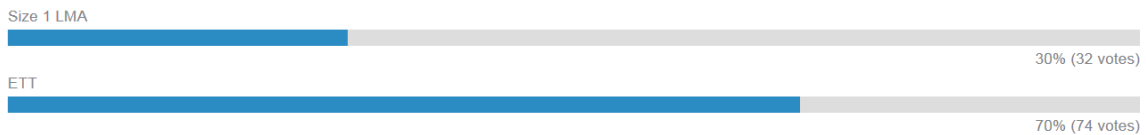
A small study of serial MRIs on the same patients using different airway devices compared MRI image quality of patients having sedation with no airway instrumentation and with an LMA in situ. They found that vibrations and head micromotions were less when the patients had an LMA in situ, which allowed for higher image quality. This study was not large enough to compare image quality between those intubated and those with an LMA (6). This Texan group commented on their clinical practice using minimally invasive airway techniques for MRIs rather than tracheal intubation. They

did not specify if this also applied to the neonatal/infant population. They reminded us of the recommendation from Dr Archie Brain that pilot balloons should be taped outside the field to minimise artefact (7).

The degree of image artefact with six different supraglottic devices were tested in a simulation study (8). The LMA Classic™, LMA Unique™ and LMA Supreme™ performed similarly in terms of artifact. The LMA ProSeal™ had the greatest amount of artefact (it is MRI incompatible due to the stainless-steel coil which reinforces the tube). They found no artifacts with the iGel™ and the Ambu™ Disposable LMA. It has, however, been commented on that the position of the iGel™ may interfere with the proper positioning of MRI head coils (7).

## Results

106 respondents completed this online survey. Of these, 32 (30%) would use a Size 1 LMA and 74 (70%) would use an endotracheal tube for a 4kg patient undergoing an MRI scan.



## Discussion

There are no explicit guidelines on airway choice for MRI and so it is for the anaesthetist to decide what is the safest practice for that child. If an LMA is selected for an MRI head scan, it is worth considering which provides the least artefact and remembering to tape the pilot balloon.

Although more respondents to this survey opted for intubating this patient, management will vary on a case by case basis. Factors which may influence the anaesthetist's choice may include the patient's condition, whether breath holding is required, frequency with which they anaesthetise patients for MRIs, the experience of the anaesthetist/anaesthetic nurse, the level of staff training, the available equipment and the environment.

Above all, the safest option must be chosen and the anaesthetic should be administered by an anaesthetist familiar with, and trained in, the MRI environment.

**Dr Alyson Walker, Consultant Paediatric Anaesthetist, Royal Hospital for Children, Glasgow**

## References

1. Arthurs OJ, Sury M. Anaesthesia or sedation for paediatric MRI: advantages and disadvantages. *Curr Opin Anaesthesiol* 2013;**26**:489-94
2. AAGBI Safety Guideline Update. Safety in Magnetic Resonance Units: An update. AAGBI. July 2010.
3. Stuart G, Understanding Magnetic Resonance Imagine: Anaesthesia Tutorial of the Week 177. 3<sup>rd</sup> May 2010.  
<http://www.frca.co.uk/Documents/177%20Understanding%20Magnetic%20resonance%20imaging.pdf> Accessed 2<sup>nd</sup> April 2016.
4. Bordes M, Semjen F, Sautereau A, *et al.* Which anaesthesia for children undergoing MRI? An internet survey in the French university hospitals. *Ann Fr Anessth Reanim* 2007;**26**: 287-291
5. Malviya S *et al.* Sedation and general anaesthesia in children undergoing MRI and CT: adverse events and outcomes. *Br J Anaesth* 2000; **84(6)**:743-8
6. Ucisik-Keser FE, Chi TL, Hamid Y, Dinh A, Chang E, Ferson DZ. Impact of airway management strategies on magnetic resonance image quality. *Br J Anaesth* 117(S1):i97-i102 (2016).
7. Brain AI. The laryngeal mask – a new concept in airway management. *Br J Anaesth* 1983;**55**:801-5.
8. Zaballos M, Bastida E, Del Castillo *et al.* In vitro study of the magnetic resonance imaging artifacts of six supraglottic airway devices. *Eur J Anaesthesiol* 2010;**27**:244-5.